

# Investigation of the eyelids with meibography in eyes with gold weight implantation after facial paralysis and comparison with healthy fellow eye

Husna Topcu<sup>1</sup>, Gunes Gumus Kasapoglu<sup>1</sup>, Ayse Cetin Efe<sup>1</sup>, Mehmet Goksel Ulas<sup>1</sup>, Kubra Serefoglu Cabuk<sup>3</sup>

## ABSTRACT

**Purpose:** To investigate ocular surface parameters and meibomian gland dysfunction in patients who have undergone gold weight implantation for facial nerve palsy and to determine the possible relationship between eyelid weight implantation and meibomian gland dysfunction.

**Materials and Methods:** This observational study was conducted, including 34 eyes of 17 patients with unilateral facial nerve palsy. Several parameters were compared between the affected (paralytic) eyes and the unaffected (fellow) eyes, including non-invasive tear break-up time (NI-TBUT), corneal fluorescein staining, meibomian gland dropout (MGDo), and meibography score (MS). Spearman correlation analysis was performed to determine any associations between the gold weight parameters and meibomian gland dysfunction.

**Results:** The paralytic eyes exhibited significantly lower NI-TBUT values ( $p=0.001$ ) and higher corneal fluorescein staining ( $p<0.001$ ) compared to the fellow eyes. Furthermore, both the upper and lower eyelids of the paralytic side showed higher MGDo and MS values (each  $p$ -value  $<0.001$ ). There were no significant differences in MGDo and MS between the lower and upper lids on both sides (each  $p>0.05$ ). Moreover, no significant correlation was found between meibomian gland dysfunction and the weight of the gold implant or the duration of implantation ( $p>0.05$ ).

**Conclusions:** While meibomian gland dysfunction is commonly observed in eyes with paralytic lagophthalmos, the findings of this study suggest that eyelid weight implantation has no significant impact on meibomian gland function.

**Keywords:** Facial paralysis, gold weight implantation, lagophthalmos, meibomian gland, non-invasive tear break-up time (NI-TBUT).

## INTRODUCTION

The treatment of paralytic lagophthalmos, which occurs as a result of facial nerve damage, focuses on preserving the ocular surface and maintaining visual acuity. These patients face various ocular surface problems such as dry eye, reflex lacrimation, and disruption of the tear film due to the loss of dynamic activity of the orbicularis oculi. If left untreated, these issues can progress from punctate epitheliopathy to corneal ulceration, keratitis, and potential vision loss.<sup>1</sup> The management of paralytic lagophthalmos depends on the underlying cause and the expected recovery time.<sup>2</sup> In short-

term and mild cases, approaches such as lubrication and taping may be effective. However, surgical interventions are necessary for treating prolonged lagophthalmos.<sup>3</sup> Among the surgical techniques, gold-weight implantation is a widely accepted and effective method for addressing paralytic lagophthalmos. This technique has been widely accepted due to its low complication rate and relative simplicity of surgical procedures.<sup>4</sup>

Meibomian glands, located within the tarsal plates of the upper and lower eyelids, are modified sebaceous glands that secrete lipid-rich substances called meibum, akin to

1- MD, Beyoglu Eye Training and Research Hospital, University of Health Sciences, Istanbul, Türkiye

2- MD, Beyoglu Eye Training and Research Hospital, University of Health Sciences, Istanbul, Türkiye

3- MD, Assoc Prof, Basaksehir Cam and Sakura City Hospital, University of Health Sciences, Istanbul, Türkiye

Received: 14.08.2023

Accepted: 06.10.2023

TJ-CEO 2024; 19: 63-68

DOI: 10.37844/TJ-CEO.2024.19.11

Correspondence author:

Husna Topcu

Email: husnaozturk@gmail.com

sebaceous gland secretions in the skin.<sup>5</sup> Meibomian gland dysfunction (MGD) is the leading cause of evaporative dry eye and results in an imbalance in the tear film due to a deficiency in the lipid layer. Meibography, a valuable non-invasive imaging tool, enables visualization of the in vivo morphology of meibomian glands, facilitating clinical assessment of MGD.<sup>6</sup>

The objective of this study was to investigate the impact of facial paralysis itself, as well as gold weight implantation in the eyelid for the subsequent treatment of paralytic lagophthalmos, on meibomian gland function. Specifically, we aimed to assess corneal staining patterns, changes observed via meibography, and non-invasive tear break-up time (NI-TBUT) in paralytic eyes with gold weight implantation, comparing these findings with those of healthy fellow eyes. To the best of our knowledge, no prior study has evaluated meibography in gold-weight-implanted eyelids.

## MATERIALS AND METHODS

In this observational study conducted at Beyoglu Eye Training and Research Hospital, the researchers focused on patients who had undergone upper eyelid gold weight implantation following facial paralysis between the years 2016 and 2021. The study was approved by the Istanbul Training and Research Ethics Committee (date and approval number: 2023/178) and adhered to the principles outlined in the Declaration of Helsinki.

The inclusion criteria consisted of patients who had undergone gold weight implantation after facial paralysis. Patients with a history of previous surgeries other than gold-weight implantation and who experienced any complications following the gold-weight implantation surgery were also excluded.

After a comprehensive ophthalmologic examination, lagophthalmos and margin lid reflex distance (MRD-1) measurements were performed in all cases. The duration of time the gold-weight implant remained in the eyelid and the weight of the implant used was recorded. Follow-up periods of the cases were noted.

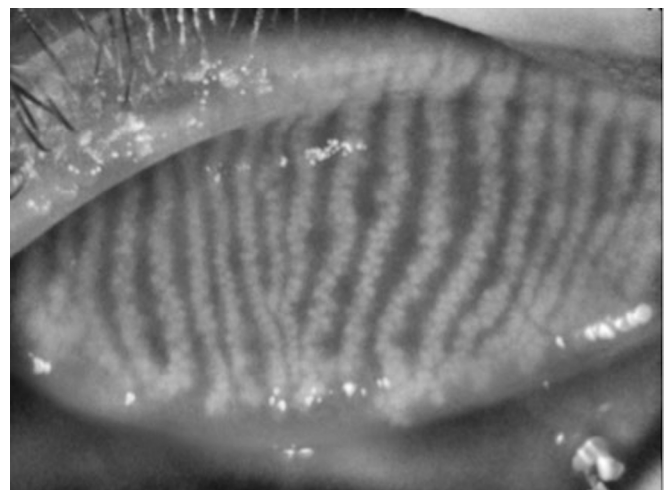
Non-invasive TBUT measurement was performed before ophthalmological examination with topography (Sirius® Scheimpflug Camera (C.S.O, Costruzione Strumenti Oftalmici, Florence, Italy). The cornea was stained with fluorescein dye to evaluate for dye uptake. The area of superficial punctate keratopathy was graded as follows: 0 (none), 1 (less than 1/3 of the cornea), 2 (between 1/3 and

2/3 of the cornea), and 3 (more than 2/3 of the cornea).<sup>7</sup>

The morphology of the meibomian glands was evaluated by non-invasive meibography integrated into the tomography device after the eversion of the upper and lower eyelids. Digital meibography images were analyzed using the automatic software supplied with the device. The meibomian gland drop-out (MGDo) was calculated by comparing the area of meibomian gland loss with the total tarsal area (Figure 1).<sup>8</sup> The meibography score (MS) was graded as previously defined<sup>9</sup>: grade 0 (no meibomian gland loss), grade 1 (meibomian gland area loss <25%), grade 2 (meibomian gland area loss >25% and <50%), grade 3 (meibomian gland area loss >50% and <75%), grade 4 (meibomian gland loss >75%). The MS was analyzed separately for the upper and lower eyelids. The meibography score for the whole eye was calculated by summing the upper and lower eyelids.

## Statistical analysis

Statistical analysis was performed using SPSS 26.0 software (IBM Corp., Armonk, NY, USA). Descriptive statistics were used to describe the characteristics of the study population. Continuous data were expressed as mean, standard deviation (SD), and minimum-maximum values. The normality of the distribution of continuous variables was tested by the Shapiro-Wilk test. Independent Sample T-test and Chi-Square test were used to compare clinical parameters between eyes. One-way ANOVA test and Tukey post hoc analysis were used to compare the upper and lower eyelids of the paralytic and fellow eye. The Spearman correlation test was performed to evaluate the relationship between implanted gold weight and meibography parameters.  $p < 0.05$  was considered statistically significant.



**Figure 1:** The meibography image of a healthy eye

**RESULTS**

The study included 34 eyes of 17 patients. Ten were female (58.8%) and seven were male (41.2%). The mean age was 46.18±15.46 years. The paralytic eye was the right eye in 11 patients (64.7%) and the left eye in 6 patients (35.3%). BCVA was 0.61±1.00 (logMar), mean MRD-1 was 2.76±1.14 mm, lagophthalmos was 1.24±0.83 mm, and NI-TBUT was 7.00±2.90 s in the paralytic eye. In the paralytic eye, corneal fluorescein staining grade was grade 0 in 1 case, grade 1 in 7 cases, and grade 2 in 9 cases. In the fellow eye, fluorescein staining was grade 0 in 10 cases and grade 1 in 7 cases. Table 1 presents the comparison of the clinical parameters between the paralytic and fellow eye.

The implanted gold weight averaged 1.28±0.25 g. The interval between gold weight implantation and meibography was 32.88±18.15 months. The total follow-up period was 38.53±24.02 months.

The MGDo and MS data obtained from the upper and lower lid of the paralytic and fellow eyes are presented in Table 2. The meibography parameters obtained from the upper and lower eyelids were statistically similar within each eye (each p-value>0.05). The total of MGDo in the

paralytic eye was 94.36±39.12 and in the fellow eye was 40.58±15.56 (p<0.001). The total MS was 4.84±1.62 and 2.23±0.83, respectively (p<0.001). Meibography images of the paralytic eyelids are presented in Figure 2; the red-shaded areas indicate meibomian gland loss.

The correlation between the parameters of the implanted gold weight and meibomian gland parameters data was investigated. Table 3 shows the correlation analysis of the data.

**DISCUSSION**

Following facial nerve palsy, the affected eye may experience problems such as lagophthalmos, evaporative dry eye, keratitis, corneal erosion, and ulceration.<sup>10</sup> Previous studies have emphasized the frequency of meibomian gland loss and evaporative dry eye in cases of paralytic lagophthalmos.<sup>11-13</sup> However, the impact of eyelid weight implantation, one of the surgical treatments used in these patients, on the meibomian glands has not been investigated. In the present study, we investigated whether gold weight implantation has an additional effect on the ocular surface and meibomian glands in patients with paralytic lagophthalmos and revealed that paralysis

**Table 1:** Comparison of eyelid and corneal parameters between paralytic eyes and matched fellow eyes


	Paralytic Eye (n=17)	Fellow Eye (n=17)	p value
BCVA, logMar	0.61±1.00	0.27±0.41	0.209
MRD-1, mm	2.76 ±1.14	3.82±0.63	<b>0.002</b>
Lagophthalmos, mm	1.24±0.83	0.00	<b>&lt;0.001</b>
NI-TBUT, sn	7.00±2.90	10.93±2.91	<b>0.001</b>
Corneal fluorescein staining, grade	1.47±0.62	0.41±0.50	<b>&lt;0.001</b>

Data are presented as mean ± SD. p values <0.05 are shown in bold.  
 BCVA; best corrected visual acuity, MRD-1; margin reflex distance-1, NI-TBUT; non-invasive tear break-up time

**Table 2:** Comparison of meibom gland drop-out and meibography score between eyelids in the paralytic and fellow eye.

	Paralytic Eye (n=17)		Fellow Eye (n=17)		p	p <sup>1†</sup>	p <sup>2‡</sup>	p <sup>3‡</sup>	p <sup>4‡</sup>
	Upper Eyelid	Lower Eyelid	Upper Eyelid	Lower Eyelid					
MGDo (mean ± SD)	48.69±17.22	42.48±22.94	25.02±8.78	22.58±12.57	<b>&lt;0.001</b>	0.683	<b>&lt;0.001</b>	<b>0.004</b>	0.972
MS (mean ± SD)	2.41±0.87	2.24±0.97	1.41±0.50	1.12±0.69	<b>&lt;0.001</b>	0.912	<b>0.002</b>	<b>0.001</b>	0.692

Data are presented as mean ± SD. p values <0.05 are shown in bold.  
 p<sup>1†</sup>: pairwise comparison between paralytic eye upper eyelid and lower eyelid  
 p<sup>2‡</sup>: pairwise comparison between paralytic eye upper eyelid and fellow eye upper eyelid  
 p<sup>3‡</sup>: pairwise comparison between paralytic eye lower eyelid and fellow eye lower eyelid  
 p<sup>4‡</sup>: pairwise comparison between fellow eye upper eyelid and lower eyelid  
 MGDo: meibom gland drop-out, MS: meibography score



**Figure 2:** Meibography images of the paralytic eyelids

**Table 3:** Correlation analysis of implanted gold weight and meibomian gland parameters

	MGDo (upper eyelid)	MS (upper eyelid)	Corneal fluorescein staining, grade
Gold weight, g	r=0.256 p=0.436	r=0.290 p=0.258	r=0.212 p=0.414
Implantation period of the gold weight, month	r=-0.384 p=0.128	r=-0.382 p=0.131	r=0.259 p=0.316
Corneal fluorescein staining, grade	<b>r=0.452**</b> <b>p=0.007</b>	<b>r=0.361*</b> <b>p=0.036</b>	

*p* values <0.05 are shown in bold.  
 \*\* Correlation is significant at the 0.01 level (2-tailed) \* Correlation is significant at the 0.05 level (2-tailed)  
 MGDo: meibom gland drop-out, MS: meibography score

affects the Meibomian glands but the gold weight has no additional effect.

Ekin et al. demonstrated a reduction in tear break-up time and a significant increase in the area and intensity of corneal fluorescein staining in eyes with facial nerve palsy.<sup>12</sup> In these cases, several factors act to disrupt the balanced distribution of tears on the ocular surface. These factors include decreased tonus of the orbicularis oculi muscle, loss of lacrimal pump function, impaired blink reflex, decreased resistance of periocular tissues to gravity, and lower lid punctum ectropion.<sup>14,15</sup> Moreover, a decrease in the number and function of meibomian glands leads to a decrease in the lipid component of tears. Consequently, tears evaporate more readily from the ocular surface due to structural and functional effects.<sup>16</sup>

It has been shown that the area of meibomian gland loss and MS are higher in cases of facial palsy compared to healthy eyes. This loss was also correlated with the severity and duration of facial nerve palsy.<sup>12</sup> Consistent with previous

findings, we found a greater MGDo and higher MS in both the upper and lower lids in the paralytic eye compared to the fellow eye. We also observed a significant correlation between the MGDo and the MS and the degree of corneal fluorescein staining in these eyes. Although the presence and severity of keratopathy resulting from lagophthalmos play a pivotal role in determining treatment approaches, the impact of meibomian gland loss on ocular surface instability should not be underestimated.

A systematic approach is crucial for successful therapeutic outcomes, considering the various procedures available for the treatment of paralytic lagophthalmos. The efficacy of eyelid weight implantation, either as a standalone procedure or in combination with other techniques, has been well-established.<sup>17</sup> Upper eyelid weight implantation is commonly performed due to its relatively simple surgical technique and low risk of complications.<sup>4,18</sup> Gold is the preferred material for implants due to its inert nature, color compatibility, and ease of shaping.

In our study, the mean weight of gold implanted was  $1.28 \pm 0.25$  g, and the average duration between gold weight implantation and meibography was  $32.88 \pm 18.15$  months. While there was a significant increase in MGD<sub>o</sub> and MS in both the upper and lower eyelids of the paralytic eye compared to the fellow eye, no significant differences were observed in MGD<sub>o</sub> and MS between the upper and lower eyelids (each  $p$  value  $> 0.05$ ). Considering that the gold weight remained implanted in the tarsus of the upper eyelid for an adequate period to assess its effects, it can be concluded that there was no additional impact on the meibomian glands.

Complications associated with implants include poor cosmesis, migration, extrusion, allergies, and astigmatism.<sup>4,19</sup> In our cases of gold weight implantation, encountered complications that included allergy, foreign body reaction, visibility, and extrusion. However, patients who experienced complications were excluded from the study and not included in this cohort.

Besides the small sample size, this study had several limitations. Factors such as age, gender, race, systemic diseases, and various factors influencing eyelid tension were not controlled for in the meibography analysis. Therefore, the present results should be interpreted in association rather than as a causal relationship. Patients were evaluated at a single time point, and it is not possible to determine with certainty whether they had normal meibomian gland function before the onset of facial nerve palsy or before gold weight implantation. Only by examining data from healthy fellow eyes can we gain some insight. If meibography had been performed before gold-weight implantation, a more accurate cause-effect relationship could have been observed.

In conclusion, the findings of this study demonstrate a loss of the meibomian gland area in both the upper and lower eyelids and an increase in meibography score on the paralytic side compared to the healthy fellow eye. However, it can be concluded that gold-weight implantation has no significant effect on the anatomy and function of the meibomian glands.

## Declarations

**Conflicts of Interest and Source of Funding:** The authors declare no potential conflicts of interest or financial relationships related to research, writing, and/or publishing this article.

**Authors' contributions:** All authors contributed to the study's conception and design. All authors commented on

previous versions of the manuscript, read, and approved the final manuscript.

**Ethics approval:** The study received approval from the local ethics committee. Written, informed consent was obtained from the patients to publish this manuscript and any accompanying images.

## REFERENCES

- Mavrikakis I, Beckingsale P, Lee E, et al. Changes in corneal topography with upper eyelid gold weight implants. *Ophthalmic Plast Reconstr Surg* 2006;22:331-4. <https://doi.org/10.1097/01.iop.0000231774.70194.3f>
- Rita MRH, Deepa M, Gitanjali VC, et al. Lagophthalmos: An etiological lookout to frame the decision for management. *Indian J Ophthalmol* 2022;70:3077-82. [https://doi.org/10.4103/ijo.IJO\\_3017\\_21](https://doi.org/10.4103/ijo.IJO_3017_21)
- Pereira MVC, Glória AL. Lagophthalmos. *Semin Ophthalmol* 2010;25:72-8. <https://doi.org/10.3109/08820538.2010.488578>
- Rofagha S, Seiff SR. Long-term results for the use of gold eyelid load weights in the management of facial paralysis. *Plast Reconstr Surg* 2010;125:142-9. <https://doi.org/10.1097/PRS.0b013e3181c2a4f2>
- Narang P, Donthineni PR, D'Souza S, et al. Evaporative dry eye disease due to meibomian gland dysfunction: preferred practice pattern guidelines for diagnosis and treatment. *Indian J Ophthalmol* 2023;71:1348-56. [https://doi.org/10.4103/IJO.IJO\\_2841\\_22](https://doi.org/10.4103/IJO.IJO_2841_22)
- Arita R. Validity of noninvasive meibography systems: noncontact meibography equipped with a slit-lamp and a mobile pen-shaped meibograph. *Cornea* 2013;32(Suppl 1):S65-70. <https://doi.org/10.1097/ICO.0b013e3182a2c7c6>
- Miyata K, Amano S, Sawa M, et al. A novel grading method for superficial punctate keratopathy magnitude and its correlation with corneal epithelial permeability. *Arch Ophthalmol* 2003;121:1537-9. <https://doi.org/10.1001/archophth.121.11.1537>
- Shimazaki J, Sakata M, Tsubota K. Ocular surface changes and discomfort in patients with meibomian gland dysfunction. *Arch Ophthalmol* 1995;113:1266-70. <https://doi.org/10.1001/archophth.1995.01100100054027>
- Pult H, Riede-Pult B. Comparison of subjective grading and objective assessment in meibography. *Cont Lens Anterior Eye* 2013;36:22-7. <https://doi.org/10.1016/j.clae.2012.10.074>
- Seiff SR, Chang JS. The staged management of ophthalmic complications of facial nerve palsy. *Ophthalmic Plast Reconstr Surg* 1993;9:241-9. <https://doi.org/10.1097/00002341-199312000-00003>

11. Takahashi Y, Kakizaki H. Meibomian gland dysfunction in cranial nerve VII palsy. *Ophthalmic Plast Reconstr Surg* 2015;31:179-81. <https://doi.org/10.1097/IOP.0000000000000235>
12. Ekin MA, Ugurlu SK, Imre SS, et al. The role of meibomian gland dysfunction on the development of dry eye disease in patients with facial nerve palsy. *Arq Bras Oftalmol* 2021;85:128-35. <https://doi.org/10.5935/0004-2749.20220021>
13. Shah CT, Blount AL, Nguyen EV, et al. Cranial nerve seven palsy and its influence on meibomian gland function. *Ophthalmic Plast Reconstr Surg* 2012;28:166-8. <https://doi.org/10.1097/IOP.0b013e31823f2f82>
14. Bergeron CM, Moe KS. The evaluation and treatment of upper eyelid paralysis. *Facial Plast Surg* 2008;24:220-30. <https://doi.org/10.1055/s-2008-1075838>
15. Bergeron CM, Moe KS. The evaluation and treatment of lower eyelid paralysis. *Facial Plast Surg* 2008;24:231-41. <https://doi.org/10.1055/s-2008-1075839>
16. Chhadva P, Goldhardt R, Galor A. Meibomian gland disease: the role of gland dysfunction in dry eye disease. *Ophthalmology* 2017;124:S20-6. <https://doi.org/10.1016/j.optha.2017.05.031>
17. Vásquez LM, Medel R. Lagophthalmos after facial palsy: current therapeutic options. *Ophthalmic Res* 2014;52:165-9. <https://doi.org/10.1159/000365519>
18. Neuman AR, Weinberg A, Sela M, et al. The correction of seventh nerve palsy lagophthalmos with gold lid load (16 years experience). *Ann Plast Surg* 1989;22:142-5. <https://doi.org/10.1097/0000637-198902000-00009>
19. Saleh GM, Mavrikakis I, de Sousa JL, et al. Corneal astigmatism with upper eyelid gold weight implantation using the combined high pretarsal and levator fixation technique. *Ophthalmic Plast Reconstr Surg* 2007;23:381-3. <https://doi.org/10.1097/IOP.0b013e318142cf88>